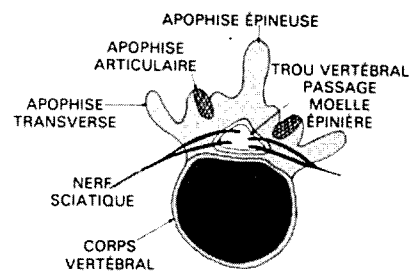
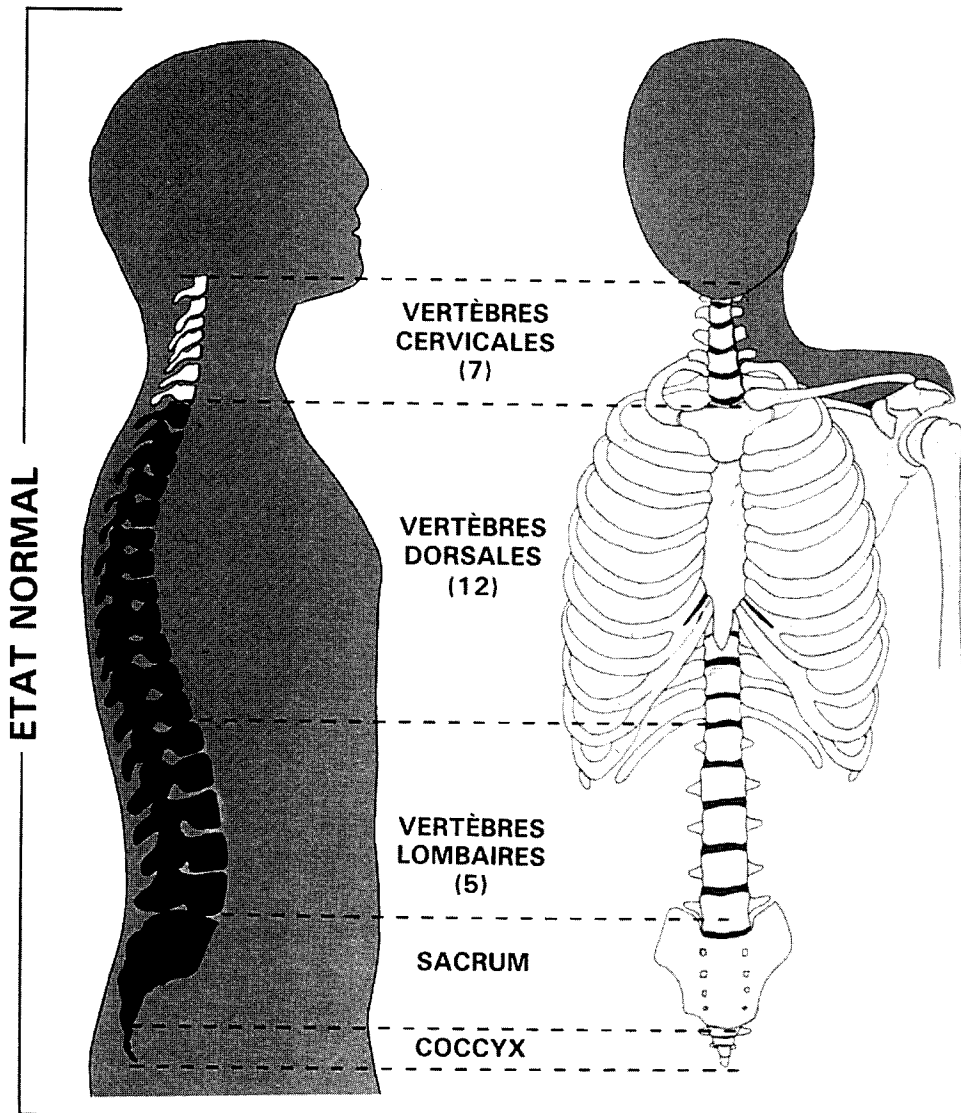
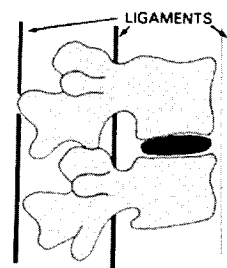


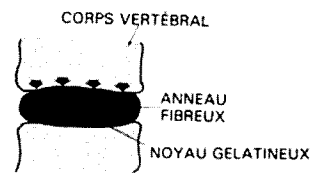
LA COLONNE VERTÉBRALE



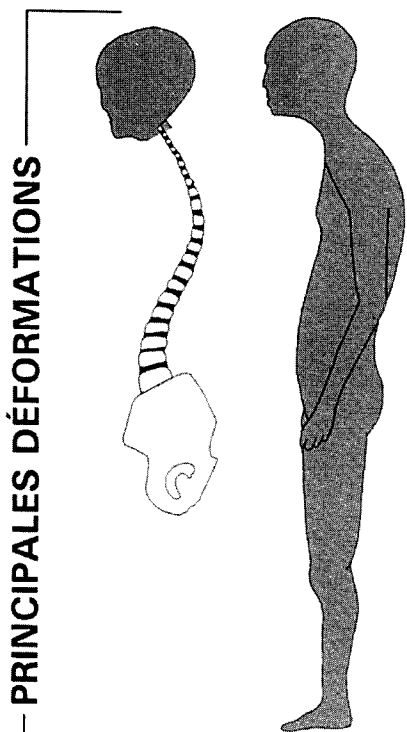
VERTÈBRE LOMBAIRE (VUE DE DESSUS)



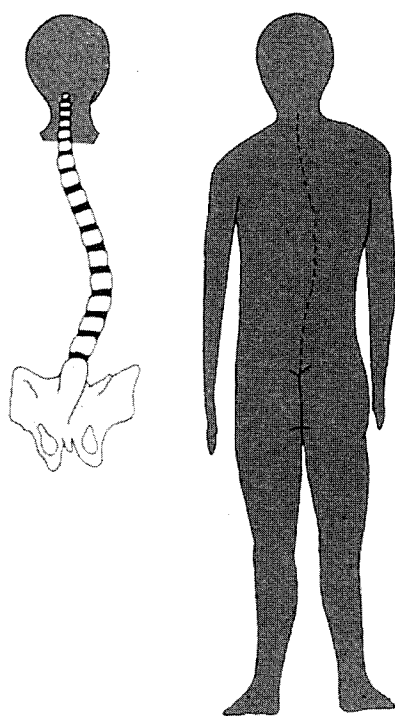
UNITÉ FONCTIONNELLE (VUE DE PROFIL)



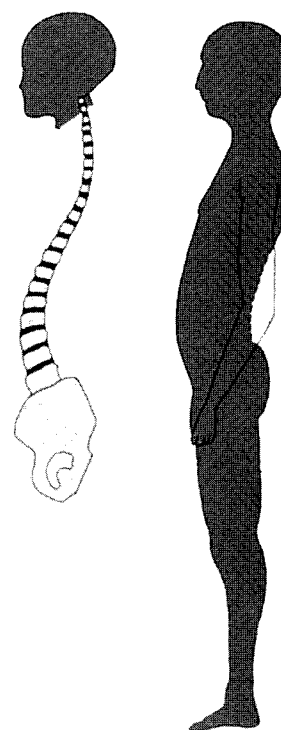
DISQUE INTER-VERTÉBRAL (VUE DE PROFIL)



CYPHOSE



SCOLIOSE



LORDOSE